

Different Expression of μ -Opiate Receptor in Chronic and Acute Wounds and the Effect of β -Endorphin on Transforming Growth Factor β Type II Receptor and Cytokeratin 16 Expression

P.L. Bigliardi,*[†] L.T. Sumanovski,*[†] S. Büchner,* T. Ruffli* and M. Bigliardi-Qi*[†]

*Department of Dermatology and [†]Department of Research, University of Basel, and [‡]Department of Dermatology, Kantonsspital Schaffhausen, Switzerland

There is evidence that neuropeptides, especially the opiate receptor agonists, are involved in wound healing. We have previously observed that β -endorphin, the endogenous ligand for the μ -opiate receptor, stimulates the expression of cytokeratin 16 in a dose-dependent manner in human skin organ cultures. Cytokeratin 16 is expressed in hyperproliferative epidermis such as psoriasis and wound healing. Therefore we were interested to study whether epidermal μ -opiate receptor expression is changed at the wound margins in acute and chronic wounds. Using classical and confocal microscopy, we were able to compare the expression level of μ -opiate receptors and the influence of β -endorphin on transforming growth factor β type II receptor in organ culture. Our results show indeed a significantly decreased expression of μ -opiate receptors on keratinocytes close to the wound margin of chronic wounds

compared to acute wounds. Additionally β -endorphin upregulates the expression of transforming growth factor β type II receptor in human skin organ cultures. These results suggest a crucial role of opioid peptides not only in pain control but also in wound healing. Opioid peptides have already been used in animal models in treatment of wounds; they induce fibroblast proliferation and growth of capillaries, and accelerate the maturation of granulation tissue and the epithelization of the defect. Furthermore opioid peptides may fine-tune pain and the inflammatory response while healing takes place. This new knowledge could potentially be used to design new locally applied drugs to improve the healing of painful chronic wounds. **Key words:** β -endorphin/chronic and acute wounds/cytokeratin 16/epidermis/ \pm -opiate receptor/TGF- β receptor II/wound healing. *J Invest Dermatol* 120:145–152, 2003

wow!!

Opioid peptides are produced by neurons in the central and peripheral nervous system. Cells from other organs are also able to produce and secrete opioid peptides, however, such as enkephalins and endorphins. Several types of cells in the skin, including immune cells and keratinocytes, produce opioid peptides. These endogenous opioid peptides interact directly with opiate receptors in skin located on immune cells and nociceptive nerve endings (Nissen *et al*, 1997). Furthermore we have recently shown that functionally active μ -opiate receptors are present on human epidermal keratinocytes (Bigliardi *et al*, 1998). The μ -opiate receptor is expressed in all layers of the epidermis, but it is more pronounced in the basal and suprabasal layers of epidermis. The functional activity of these opiate receptors in human epidermis was studied using skin culture experiments. Results revealed an upregulation of cytokeratin 16 (CK16) and a downregulation of the μ -opiate receptor in epidermis after incubation with the endogenous ligand β -endorphin. This effect of β -endorphin was inhibited after incubation together with the μ -opiate receptor an-

tagonist naltrexone (Bigliardi-Qi *et al*, 2000). CK16 is not expressed in normal skin, but appears in the suprabasal, differentiating compartment of the epidermis during wound healing and hyperproliferative skin diseases such as psoriasis and skin cancer (Gerritsen *et al*, 1997). Therefore the upregulation of CK16 shows the direct link of the μ -opiate receptor system in wound healing. There are several indications that neuropeptides are involved in wound healing as well. Of special interest is proopiomelanocortin (POMC). POMC is the precursor of adrenocorticotropin, β -endorphin, melanocyte stimulating hormone, and lipotropin. POMC products were consistently detected (10 of 11 cases) in the keratinocytes and mononuclear cells at keloid lesions (Slominski *et al*, 1993). It has been suggested that POMC products may accumulate locally in lesional skin, representing a novel cutaneous response to injury, and that these products are produced *in situ* by human skin. POMC products are also powerful modulators of the immune system. There are additional indications that opiate receptor agonists not only are present in wound fluid of burn wounds (Soledad Cepeda *et al*, 1993) but also promote wound healing (Kohl *et al*, 1989). Therefore we studied the expression of μ -opiate receptor in epidermis at the wound margins, especially to determine if the opiate receptor expression on keratinocytes is different in chronic and acute wounds. We were additionally interested to investigate whether the expression of receptors of growth factors crucial in wound healing are affected by the opiate receptor system. One of the most important factors in wound healing is the transforming growth factor β (TGF- β

Manuscript received April 16, 2002; revised July 26, 2002; accepted for publication July 30, 2002

[†]These authors contributed equally to this publication.

Reprint requests to: P.L. Bigliardi, Department of Dermatology, University of Basel, 4031 Basel, Switzerland; Email: paul.bigliardi@kss.ch.

Abbreviations: POMC, proopiomelanocortin; CK16, cytokeratin 16.

receptor system, especially TGF- β type II receptor, a transmembrane serine/threonine kinase. The TGF- β type II receptor is expressed in regenerating epithelial cells of acute wounds and in epithelial cells at the wound margin of chronic wounds and plays an important role in wound healing.

MATERIALS AND METHODS

Preparation of human skin organ cultures for measuring TGF- β type II receptor and CK16 expression after exposure to β -endorphin The method of functional assays with skin organ cultures was adapted from Paus *et al* (1994) and described in our previous paper (Bigliardi-Qi *et al*, 2000). Briefly skin grafts of about 0.5 mm thickness were obtained by a dermatome from the upper leg of an individual. To standardize the tissue volume and thereby the cell mass of cultured skin fragments, only punches with 4 mm diameter were used. Several randomized 4 mm skin punches per experimental group were placed on Anocell™ 10 mm tissue culture inserts (Nunc, Life Technologies, Rockville, MD). These inserts were put in a Nunclon™ 24-well plate containing 2 ml Dulbecco's modified Eagle's medium (DMEM with Glutamax-I, Life Technologies) supplemented with 10% fetal bovine serum and 50 μ g per ml gentamicin (Life Technologies). After addition of serial dilutions of the specific endogenous μ -opioid receptor agonist β -endorphin (Sigma, St. Louis, MO), the organ cultures were incubated for 48 h at 37°C in 5% CO₂ and 100% humidity. As control we incubated skin organ cultures in the culture medium only. At the end of the incubation period the organ culture pieces were fixed in 4% formaldehyde and embedded in paraffin for use in immunohistochemistry. The immunohistochemistry was performed as described above. The primary antibodies were a mouse anti-CK16 antibody (NCL-CK16, Novocastra Laboratories, Newcastle, U.K.) and a rabbit anti-TGF- β type II receptor antibody (Santa Cruz Biotechnology, Santa Cruz, CA) in separate experiments. The binding was detected using the StrAvisGen Super Sensitive™ kit (BioGenex Laboratories, San Ramon, CA), which uses biotinylated and alkaline phosphatase bound antibody. Naphthol red was used to detect the alkaline phosphatase. In order to compare directly the skin samples exposed to serial dilutions of β -endorphin, the immunohistochemistry experiments in one series were performed simultaneously in the same manner. The quantification of the immunohistochemical staining with alkaline phosphatase was performed as described below.

Staining of μ -opioid receptor on paraffin-embedded biopsies of acute and chronic wounds with alkaline phosphatase First we searched the database of the Dermatology Department of the University of Basel for biopsies of chronic and acute wounds. Fifteen patient samples were analyzed with alkaline phosphatase color staining. Six patient samples were analyzed with fluorescence labeling. The paraffin-embedded skin biopsies were cut into 4 μ m sections. The sections were dried overnight at 37°C and deparaffinized with xylol, ethanol (100%, 96%, 90%, 80%, 70%, 50%), distilled H₂O, and phosphate-buffered saline (PBS) (pH 7.0–7.2).

The immunohistochemistry method was modified from our previous method (Bigliardi-Qi *et al*, 2000). Briefly, the sections were microwave treated in sodium nitrate buffer for 10 min at 95°C and then blocked with PBS with 5% normal goat serum for 1 h. The primary rabbit anti- μ -opioid receptor antibody (Diasorin, Stillwater, MN) was added and left overnight at 4°C. The binding was detected using the StrAvisGen Super Sensitive kit, which uses biotinylated and alkaline phosphatase bound antibody. Naphthol red was used to detect the alkaline phosphatase, and Mayer's acid hematoxylin solution, containing sodium iodate, alauin, and hematoxylin, was used as counterstain. The negative controls were the sections that were not exposed to primary antibody. In order to compare the skin samples directly the immunohistochemistry experiments in one series were performed simultaneously in the same manner.

Quantification of immunohistochemical staining with alkaline phosphatase The intensities of the expression of μ -opioid receptor were quantified using a digital CCD color camera (CF 20 DXC air, Kappa Messtechnik, Gleichen, Germany) on an inverted microscope (Nikon, Diaphot 300, Tokyo, Japan). All pictures were taken under the same conditions with 50 \times magnification. The area and intensity of the naphthol red signal was quantified on an image analysis system (PicEd Cora, Jomesa, Munich, Germany). The program parameters were set up so that the control sections without incubation with primary antibody had less than 1% staining. Measurements were taken from three different sections on the same slide. The expression level was estimated as the percentage of naphthol red stained area compared to the total measured area in

epidermis. The average values and standard deviations were taken from triplicate readings. The quantification of the expression of CK16 and TGF- β type II receptor in epidermis was performed in the same way.

Confocal microscopy of immunohistochemical staining with fluorescence For fluorescence labeling, the secondary antibody was Cy5-conjugated goat antirabbit IgG (H+L) (Jackson ImmunoResearch Laboratories, West Grove, PA). The secondary antibodies had been tested for minimal cross-reaction to human, mouse, and rat serum proteins. Sections were mounted with FluorSave (Calbiochem, Darmstadt, Germany). Confocal microscopy was performed with a Zeiss Confocal

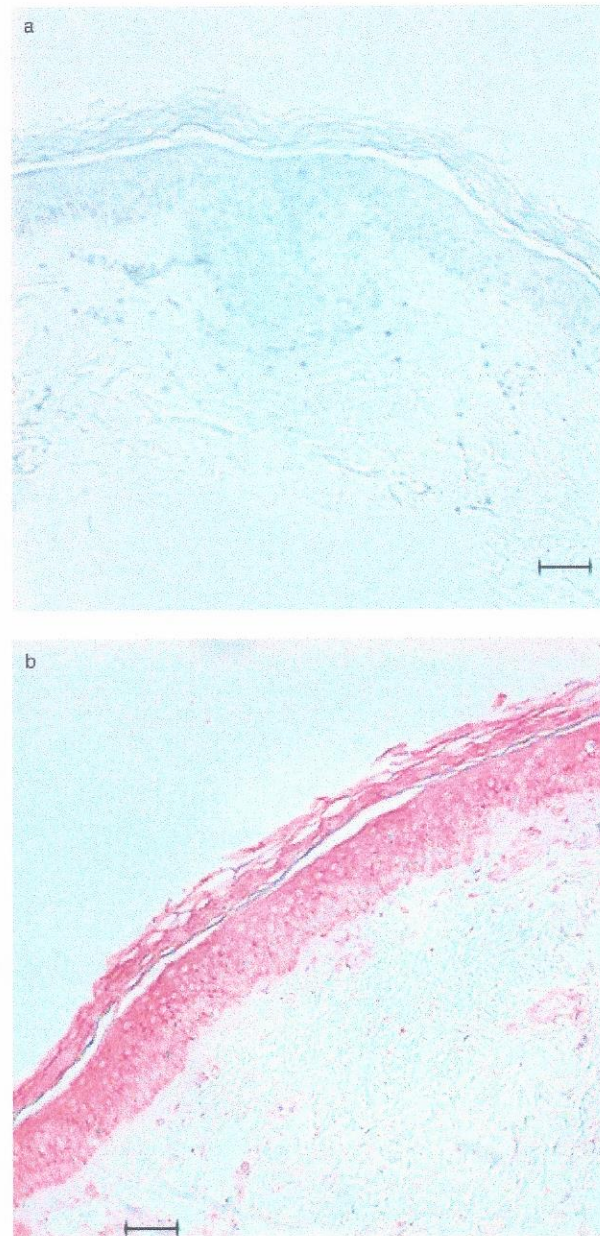


Figure 1. Upregulation of TGF- β type II receptor after exposure of human skin organ cultures to β -endorphin. The skin culture samples were incubated either without (a) or with (b) 62 nM β -endorphin for 48 h. The TGF- β type II receptor expression was determined on deparaffinized sections using naphthol red as substrate of the alkaline phosphatase. Scale bar: 50 μ m.

Laser Scanning Microscope LSM 510, inverted Axiovert 100 M (Carl Zeiss AG, Jena, Germany). It operates in the sequential acquisition mode to exclude cross-talk between channels. The 488 (for Cy2), 568 (for Cy3), and 647 (for Cy5) excitation lines were used and the optics were a Zeiss Plan-Neofluar 40 \times oil immersion objective with a numerical aperture of 1.3. Optical sections of 0.9 μ m thickness were scanned through the z plane of the sample. The three-dimensional reconstruction was done with the "Full 3D" function of the Imaris 3.0 software (Bitplane, Zürich, Switzerland). Images were quantified using the IMARIS statistic software package.

RESULTS

TGF- β type II receptor and CK16 expression in human epidermis is upregulated by β -endorphin Figure 1 shows the massive overexpression of TGF- β type II receptor after exposure of human skin organ cultures to 62 nM β -endorphin (Fig 1b) compared to skin only exposed to the medium (Fig 1a). In Fig 2 we correlate the CK16 overexpression in epidermis at various concentrations of β -endorphin with the expression of TGF- β type II receptor. Interestingly these two expression patterns look exactly the same, which means that with increasing concentrations of β -endorphin the expressions of

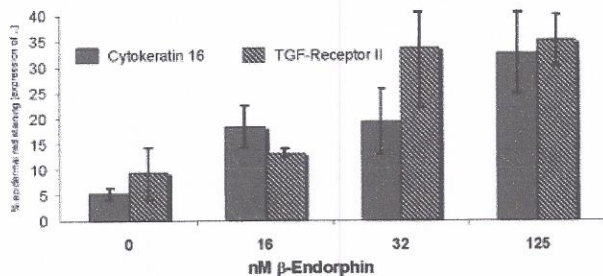


Figure 2. Upregulation of TGF- β type II receptor and CK16 after exposure of human skin organ cultures to β -endorphin. Skin culture samples were exposed to 0–125 nM β -endorphin for 48 h, and TGF- β type II receptor expression or CK16 expression was quantified by measuring the intensity of naphthol red using triplicates of digital images from three different regions of the same skin culture sample. The bars represent percentage of red stained area compared with the total epidermal area measured on three samples \pm SD.

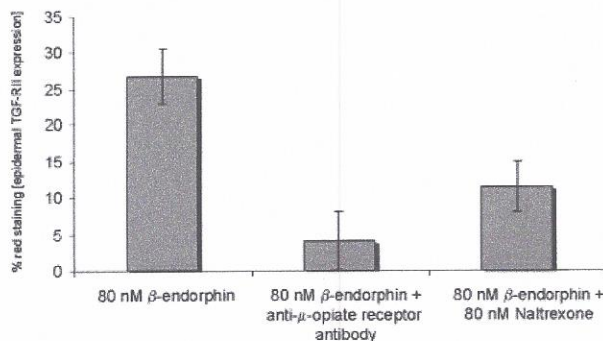


Figure 3. Blocking of the upregulation of TGF- β type II expression induced by β -endorphin in human skin organ cultures. The skin organ cultures were incubated for 48 h with 60 nM β -endorphin in the presence or absence of 80 nM polyclonal guinea pig anti- μ -opiate receptor antibody or 80 nM naltrexone. The bars represent percentage of red stained area compared with the total epidermal area measured on three samples \pm SD.

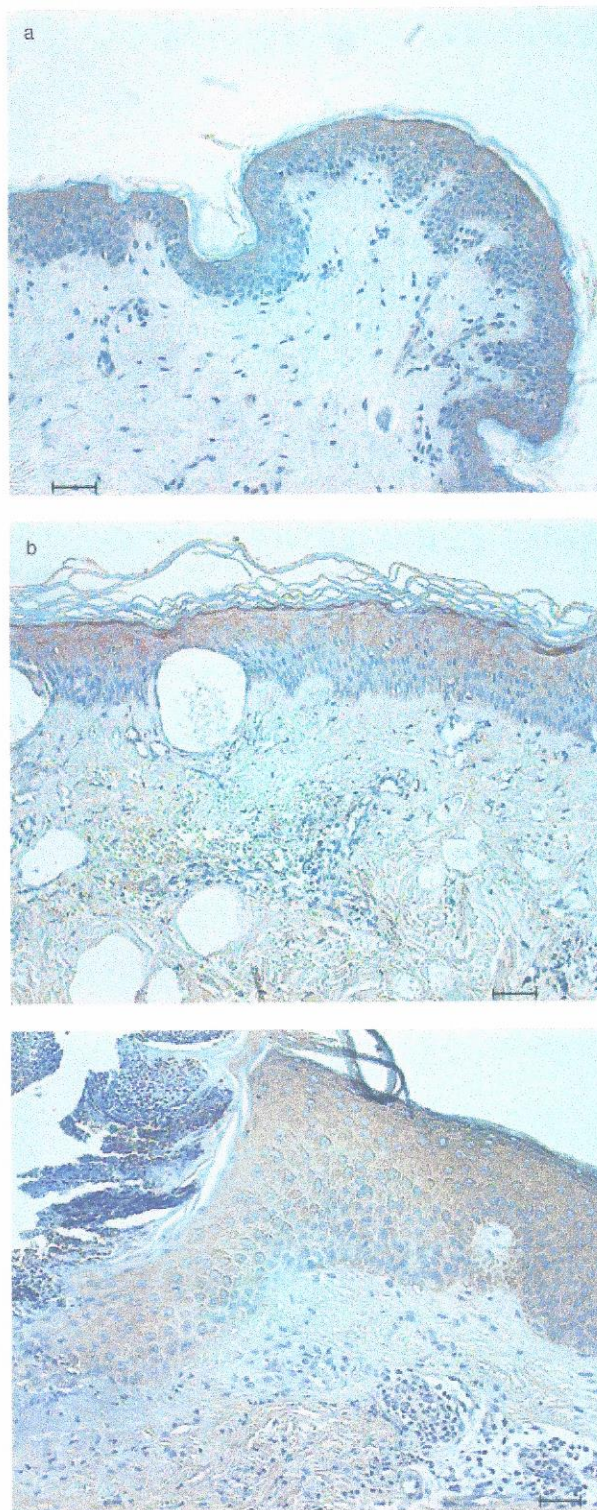


Figure 4. Normal expression of μ -opiate receptor at the wound margins of acute wounds. The expression of μ -opiate receptor in biopsies of normal skin (a), burn wound (b), and abrasion (c) was determined on deparaffinized sections using naphthol red as substrate of the alkaline phosphatase and a polyclonal rabbit anti- μ -opioid receptor antibody as primary antibody (see Materials and Methods). Scale bar: 50 μ m.

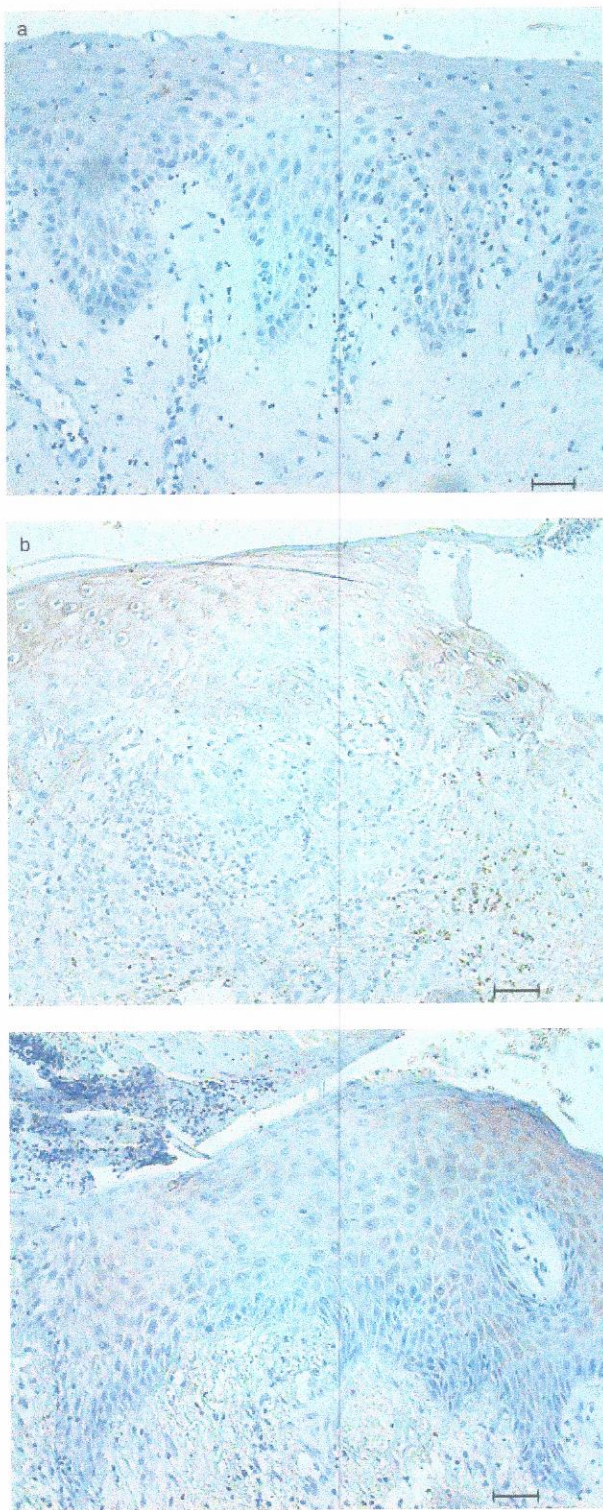


Figure 5. Dramatic downregulation of the expression of μ -opiate receptor at the wound margins of chronic wounds. The expression of μ -opiate receptor in skin biopsies of ulcer cruris (a, b) and ulcer in radioderm (c) was determined on deparaffinized sections using naphthol red as substrate of the alkaline phosphatase and a polyclonal rabbit anti- μ -opioid receptor antibody as primary antibody (see *Materials and Methods*). Scale bar: 50 μ m.

both TGF- β type II receptor and CK16 increase. Both of these factors are crucial in wound healing. With addition of naltrexone the overexpression of TGF- β type II receptor immunoreactivity could be prevented, suggesting a specific effect of β -endorphin (Fig 3).

μ -Opiate receptors are significantly less expressed at the wound margins of chronic wounds compared to acute wounds In order to test if the effects of β -endorphin on human epidermis in skin organ cultures is present in clinical specimens, we stained paraffin-embedded skin biopsies from the archives of the Department of Dermatology in Basel with antibodies for μ -opiate receptors. Biopsies from both acute and chronic wounds were tested. As shown in Fig 2, CK16 is upregulated in skin organ cultures exposed to the endogenous ligand β -endorphin. On the other hand β -endorphin downregulates the expression of μ -opiate receptor in the same skin organ cultures. Therefore we would expect the expression of the μ -opiate receptor on keratinocytes to be downregulated at the wound margins of chronic wounds, where the keratinocytes are hyperproliferative and express CK16. We observed exactly this pattern and our experiments confirmed this. In acute wounds the μ -opiate receptor expression is comparable to normal skin (Fig 4a). As acute wounds we used burn wounds (Fig 4b) and abrasio (Fig 4c) of epidermis. An abrasio is a removal of epidermis and upper parts of dermis by trauma or scratching. In chronic wounds the μ -opiate receptor expression is significantly downregulated. We defined chronic wounds as wounds that do not heal normally, for instance ulcer cruris (Fig 5a,b), wounds on the lower legs derived mostly from chronic venous hypertension. Wounds in skin previously exposed to irradiation therapy for underlying cancers also do not heal normally and can be considered as chronic wounds. The skin exposed to radiation is called radioderm (Fig 5c). At the wound margins of this skin the μ -opiate receptor is significantly downregulated compared to normal skin and epidermis at acute wounds (Fig 4a). In Fig 6 we show the results of the semiquantitative analysis of two representative experiments measuring the μ -opiate receptor expression in the epidermis of wound margins of acute and especially of chronic wounds. It shows clearly the significant downregulation of the receptor in chronic wounds.

In confocal microscopy the μ -opiate receptor expression in chronic wounds is downregulated and the expression of the ligand β -endorphin is upregulated To confirm the above observed downregulation of μ -opiate receptor in epidermis at wound margins of chronic wounds we performed a different

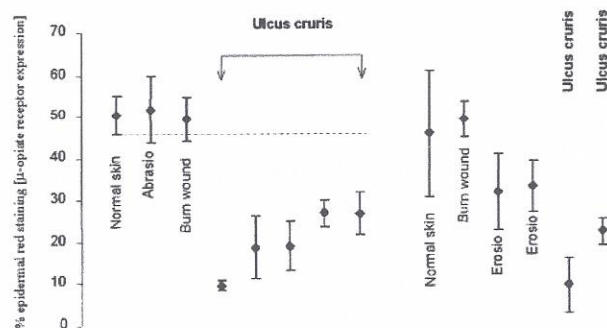


Figure 6. Downregulation of μ -opiate receptor expression in epidermis at the wound margins of chronic wounds compared to normal skin and acute wounds. The expression of μ -opiate receptor in skin biopsies from the wound margin of different acute and chronic wounds and from normal skin was determined by immunohistochemistry. The staining was conducted as described in Figs 4 and 5. The points represent percentage of red stained area compared with the total epidermal area measured on three different regions of the slide \pm SD.

kind of microscopy using immunofluorescence instead of immunohistochemistry. First the experiments confirm the downregulation of μ -opiate receptor expression in epidermis at the wound margin of ulcer cruris (Fig 7b) compared to normal skin (Fig 7a) and an acute burn wound, also from the lower leg (Fig 7c). We performed a double staining using at the same time antibodies against the ligand β -endorphin. As we would expect we observed at the wound margin of chronic wounds a remarkable upregulation of expression of the endogenous ligand β -endorphin (Fig 8b) leading to a downregulation of the receptor expression. In normal skin we see some β -endorphin expression (Fig 8a). In acute burn wounds, however (Fig 8c), we see a slightly higher expression of β -endorphin in keratinocytes.

DISCUSSION

In this paper we describe how the opiate receptor system affects epidermal cell growth and differentiation through CK16 and TGF- β type II receptor. Our previous data have shown that the expression of CK16 is upregulated by β -endorphin in skin organ culture experiments (Bigliardi-Qi *et al*, 2000). We could now show additionally that this overexpression correlates with the expression of TGF- β type II receptor. Thus CK16, an important marker of hyperproliferative differentiation patterns in wound healing, as well as TGF- β type II receptor are upregulated by 50–100 nM of β -endorphin. These concentrations of ligand could also downregulate the opiate receptor expression in epidermis, which is a sign of negative feedback.

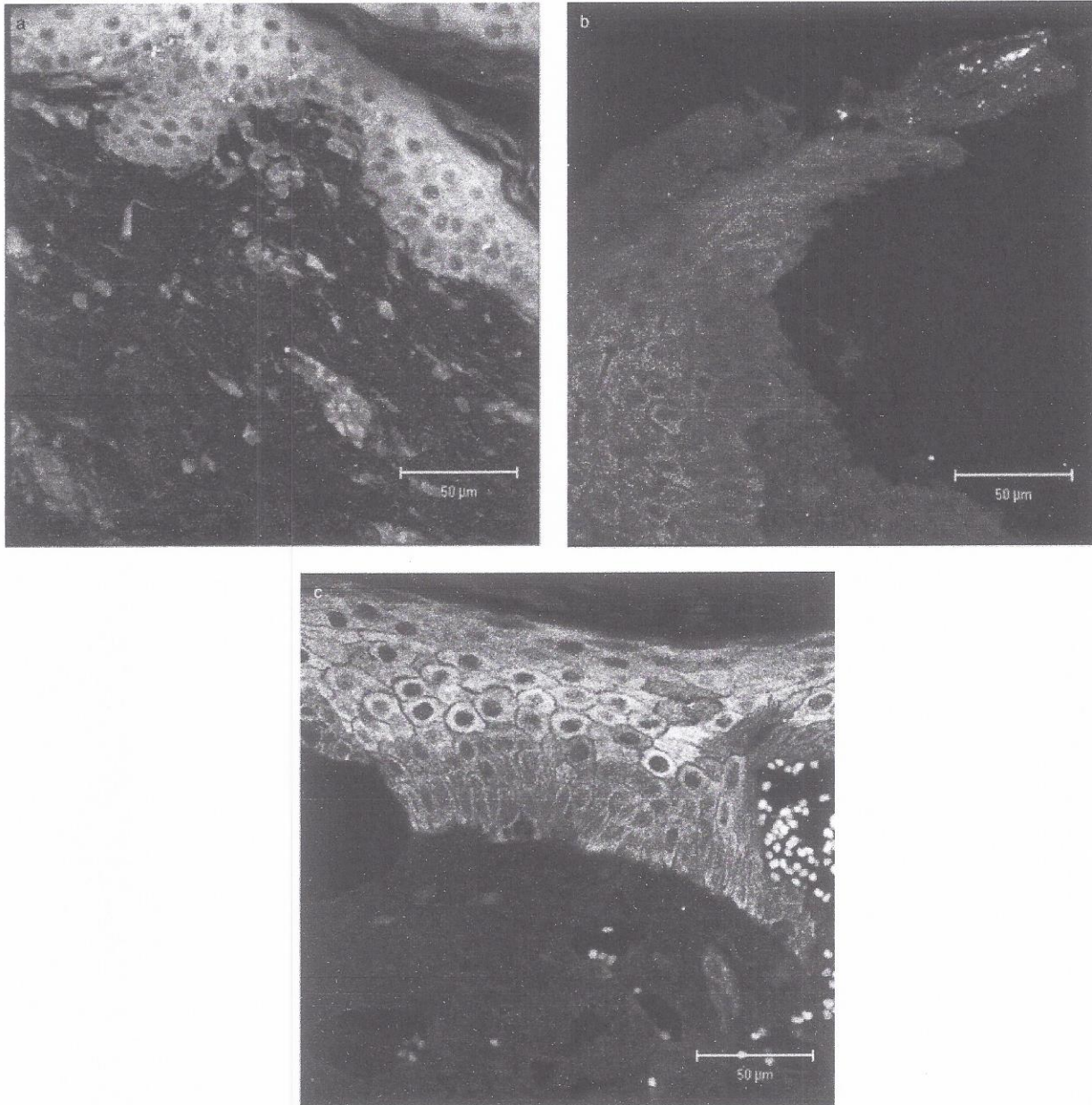


Figure 7. Downregulation of μ -opiate receptor expression at wound margins of chronic wounds by three-dimensional confocal microscopy. Three-dimensional confocal micrograph of cryostat sections (50 μ m) of normal human skin (a), chronic ulcer cruris (b), and acute burn wounds (c), stained for μ -opiate receptor with Cy-5 fluorophore (blue). The primary antibody is a polyclonal rabbit anti- μ -opiate receptor antibody. Scale bar: 50 μ m.

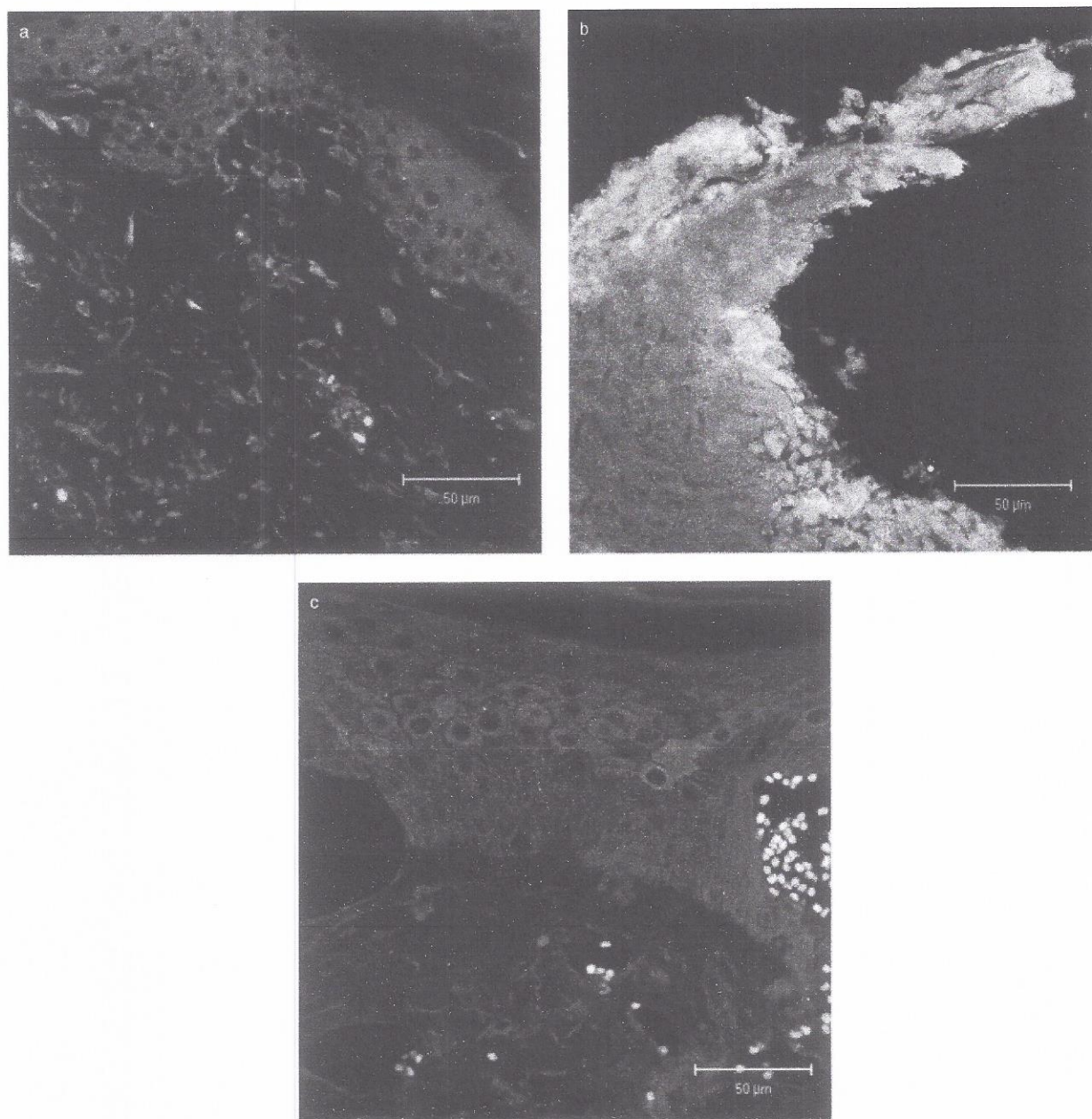


Figure 8. Upregulation of β -endorphin expression at wound margins of chronic wounds by three-dimensional confocal microscopy. Three-dimensional confocal micrograph of cryostat sections (50 μ m) of normal human skin (a), chronic ulcer cruris (b), and acute burn wounds (c), stained for β -endorphin with Cy-2 fluorophore (green). The primary antibody is a polyclonal mouse anti- β -endorphin antibody. Scale bar: 50 μ m.

Members of the TGF- β superfamily are critical regulators for epithelial growth and keratinocyte differentiation. TGF- β mediates its biologic effects through three high-affinity cell surface receptors, the TGF- β type I, type II, and type III receptors, and the Smad family of transcription factors. The precise role of the type III receptor in TGF- β signaling remains unclear. Much attention is put on the role of TGF- β in wound healing. After injury the expression of type II and I receptors and their ligands were increased in epidermis adjacent to the wound (Gold *et al*, 1997). The TGF- β signaling pathway is one of the most important mechanisms in the maintenance of epithelial homeostasis. Transgenic mice that overexpress TGF- β_1 in the suprabasal keratinocyte com-

partment showed a 2- to 3-fold increase in epidermal DNA labeling index over control mice, in the absence of hyperplasia. During induction of hyperplasia by 12-tetradecanoyl-phorbol-13-acetate TGF- β receptor I levels remained relatively constant, and TGF- β receptor II expression was strongly induced (Cui *et al*, 1995). Transduction of TGF- β signaling depends on the phosphorylation and activation of Smad proteins. Transgenic mice that overexpress Smad2 in epidermis have delayed hair growth, underdeveloped ears, and severe thickening of the epidermis. These abnormal phenotypes are due to increased proliferation of the basal epidermal cells and abnormalities in the program of keratinocyte differentiation (Ito *et al*, 2001). From our

skin organ culture experiments, in which β -endorphin upregulates TGF- β type II receptor and CK16, we could speculate that the opioid ligands also control the differentiation pattern and the expression of TGF receptors in acute and chronic wounds. Therefore the opioid receptor system in epidermis is involved in skin homeostasis through the TGF receptor system. Furthermore, as deletion of the TGF- β type II receptor accelerates skin carcinogenesis (Wang, 2001) we could hypothesize that the opiate receptor system in epidermis is involved in skin cancers as well. Indeed, we have previously observed a significant downregulation of the μ -opiate receptor in basal cell carcinoma (Bigliardi-Qi *et al*, 1999).

In nature stress is often associated with possible wounding during a fight or fleeing. During stress the POMC peptides adrenocorticotropin and β -endorphin are released locally. Therefore it is natural that the locally released β -endorphin controls the pain in the periphery. It is known that the opioid peptides have important influences on immune cells and keratinocytes besides the pain control and in the central nervous system. The role of ligands of the opiate receptor system in wound healing has been previously described. The local application in rats of the opioid peptide dalargin, a leu-enkephalin analog, induces fibroblast proliferation (3-fold increase in the mitotic index) and growth of capillaries, accelerates the maturation of granulation tissue and the epithelization of the defect, and considerably reduces the period of healing of skin wounds. The stimulating action of dalargin is associated with its effect on the microcirculation system and the activation of the macrophage-fibroblast interaction. Possessing the triggering mechanism, the drug induces a cascade of inflammatory-reparative reactions, which reduce the duration of all healing stages (Shekhter *et al*, 1988; Kohl *et al*, 1989). It has been found that the μ -opiate receptor ligand β -endorphin has an important role in limb regeneration in nonmammalian vertebrates (Vethamany-Globus *et al*, 1983). Another group (Soledad Cepeda *et al*, 1993) examined the interactions between exogenous opioid analgesia and endogenous opioid generation at a site of burn-induced tissue injury. β -Endorphin was measured in wound fluid withdrawn from subcutaneous wire mesh chambers beneath the site of a 3%–5% surface area burn in rats. The concentration of β -endorphin rose above baseline at 1, 2, and 4 h postburn, and then returned to baseline at 24 h. Systemic opioid treatment produced analgesia (by tail flick latency testing) but did not reduce intra-chamber hormone responses. Thus local β -endorphin responses at the site of thermal injury are regulated differently from systemic pituitary-adrenal responses. In humans β -endorphin concentrations in plasma are significantly increased in burn patients as well, and the amount of β -endorphin in plasma correlated positively with the extent of the burn areas ($r = 0.576$) (Xue, 1991). It is hypothesized that the elevation of circulating β -endorphin levels causes a modulation of the immune system after traumatic injury (Levy *et al*, 1986). Because keratinocytes are able to produce β -endorphin (Wintzen *et al*, 1995; Zanello *et al*, 1999), we postulate that the elevated β -endorphin concentrations in plasma and especially wound fluid not only arise from the central nervous system but also are produced in the skin by keratinocytes locally after injury.

The best studied role of opioids is in pain control, in which opioids are known to inhibit neurotransmitter release from dorsal root ganglion projections in the dorsal horn of the spinal cord (Zhang *et al*, 1998). But there are several studies indicating that opiate-induced analgesia is due to a peripheral mechanism, besides its well recognized central mechanism of action (Ferreira and Nakamura, 1979; Joris *et al*, 1987). The local administration of opioid peptides seems to relieve pain (Twilman *et al*, 1999), another important and distressing symptom in chronic wounds. The pain could also interfere with the wound healing directly.

Our results show a downregulation of μ -opiate receptor in chronic wounds and a normal epidermal expression of the receptor at the wound margin of acute wounds. High concentrations of β -endorphin downregulate the expression of the receptor in a negative feedback mechanism (Bigliardi-Qi *et al*, 2000); therefore we would expect high expressions of the ligand in chronic

wounds, and indeed in chronic wounds the expression of β -endorphin is markedly increased. In acute wounds we observe slightly more expression of β -endorphin compared to normal skin, but this does not lead to a downregulation of the receptor. This suggests that in acute wounds the ligand and the μ -opiate receptor are expressed in a balanced level, which leads to more expression of CK16 and TGF- β type II receptor. This balance is disturbed in chronic wounds, however, where the ligand is highly overexpressed and the receptor is therefore downregulated; this leads to changes in differentiation and expression of growth factors and their receptors that are involved in impaired wound healing in chronic wounds. All of these effects together underline the importance of studying neuropeptides, especially opiate receptor ligands in wound healing, which might lead to new therapy of wounds. Ligands of the opiate receptors can be used not only locally for pain control in wounds but also to improve the process of wound healing and recpithelization and to enhance hypertrophic scars through upregulation of the TGF- β system.

We would like to thank Dr. Helen Langerman for proof reading this paper and financial support from Sprig AG, Switzerland.

REFERENCES

- Bigliardi PL, Bigliardi-Qi M, Büchner S, Rüfli T: Expression of μ -opiate receptor in human epidermis and keratinocytes. *J Invest Dermatol* 111:297–301, 1998
- Bigliardi-Qi M, Bigliardi PL, Büchner S, Rüfli T: Characterization of μ -opiate receptor in human epidermis and keratinocytes. *Ann N Y Acad Sci* 885:368–371, 1999
- Bigliardi-Qi M, Bigliardi PL, Eberle AN, Büchner S, Rüfli T: β -Endorphin stimulates cytokerin 16 expression and downregulates μ -opiate receptor expression in human epidermis. *J Invest Dermatol* 114:527–532, 2000
- Cui W, Fowles DJ, Cousins FM, Duffie E, Bryson S, Balmain A, Akhurst RJ: Concerted action of TGF- β 1 and its type II receptor in control of epidermal homeostasis in transgenic mice. *Genes Dev* 9:945–955, 1995
- Ferreira SH, Nakamura MI: Prostaglandin hyperalgesia: the peripheral analgesic activity of morphine, enkephalins and opioid antagonists. *Prostaglandins* 18:191–200, 1979
- Gerritsen MJ, Elbers ME, de Jong EM, van de Kerkhof PC: Recruitment of cycling epidermal cells and expression of filaggrin, involucrin and tenascin in the margin of the active psoriatic plaque, in the uninvolved skin of psoriatic patients and in the normal healthy skin. *J Dermatol Sci* 14:179–188, 1997
- Gold LI, Sung JJ, Siebert JW, Longaker MT: Type I (RI) and type II (RII) receptors for transforming growth factor- β isoforms are expressed subsequent to transforming growth factor- β ligands during excisional wound repair. *Am J Pathol* 150:209–222, 1997
- Ito Y, Sarkar P, Mi Q, *et al*: Overexpression of Smad2 reveals its concerted action with Smad4 in regulating TGF- β -mediated epidermal homeostasis. *Dev Biol* 236:181–194, 2001
- Joris JL, Dubner R, Hargreaves KM: Opioid analgesia at peripheral sites: a target for opioids released during stress and inflammation? *Anesth Analg* 66:1277–1281, 1987
- Kohl A, Werner A, Buntrock P, Diezel W, Adrian K, Titov MI: [The effect of the peptide dalargin on wound healing]. *Dermatol Monatsschr* 175:561–572, 1989
- Levy EM, McIntosh T, Black PH: Elevation of circulating β -endorphin levels with concomitant depression of immune parameters after traumatic injury. *J Trauma* 26:246–249, 1986
- Nissen JB, Lund M, Stengaard-Pedersen K, Kragballe K: Enkephalin-like immunoreactivity in human skin is found selectively in a fraction of CD68-positive dermal cells: increase in enkephalin-positive cells in lesional psoriasis. *Arch Dermatol Res* 289:265–271, 1997
- Paus R, Lüftl M, Czarnetzki BM: Nerve growth factor modulates keratinocyte proliferation in murine skin organ culture. *Br J Dermatol* 130:174–180, 1994
- Shekhter AB, Solovèva AI, Spevak SE, Titov MI: Effects of opioid peptide dalargin on reparative processes in wound healing. *Biull Eksp Biol Med* 106:487–490, 1988
- Slominski A, Wortsman J, Mazurkiewicz JE, *et al*: Detection of proopiomelanocortin-derived antigens in normal and pathologic human skin. *J Lab Clin Med* 122:658–666, 1993
- Soledad Cepeda M, Lipkowski AW, Langlade A, *et al*: Local increases of subcutaneous β -endorphin immunoactivity at the site of thermal injury. *Immunopharmacology* 25:205–213, 1993
- Twilman RK, Long TD, Cathers TA, Mueller DW: Treatment of painful skin ulcers with topical opioids. *J Pain Symptom Manage* 17:288–292, 1999

- Vethamany-Globus S, Globus M, Milton G: A comparison of β -endorphin levels in regenerating and nonregenerating vertebrates. *J Exp Zool* 227:475-479, 1983
- Wang XJ: Role of TGF β signaling in skin carcinogenesis. *Microsc Res Tech* 52:420-429, 2001
- Wintzen M, Yaar M, Avila E, Vermeer BJ, Gilchrist BA: Keratinocytes produce β -endorphin and β -lipotropin hormone after stimulation by UV, IL-1 α or phorbol esters. *J Invest Dermatol* 104:641, 1995
- Xue JZ: [Changes in plasma immunoreactive β -endorphin in burn and its clinical significance]. *Zhonghua Zheng Xing Shao Shang Wai Ke Za Zhi* 7:253-256 317, 1991
- Zanello SB, Jackson DM, Holick MF: An immunocytochemical approach to the study of β -endorphin production in human keratinocytes using confocal microscopy. *Ann N Y Acad Sci* 885:85-99, 1999
- Zhang X, Bao L, Shi TJ, Ju G, Elde R, Hokfelt T: Down-regulation of μ -opioid receptors in rat and monkey dorsal root ganglion neurons and spinal cord after peripheral axotomy. *Neuroscience* 82:223-240, 1998